

## Effects of early postoperative hyperbaric oxygen therapy on energy metabolism and hepatic regeneration after hepatectomy

Masahiko Sakoda<sup>1</sup>, Shinichi Ueno<sup>1</sup>, Fumitake Kubo<sup>1</sup>, Kiyokazu Hiwatashi<sup>1</sup>, Kenji Kihara<sup>1</sup>, Hiroyuki Shinchi<sup>1</sup>, Kousei Maemura<sup>1</sup>, Hidetoshi Noma<sup>1</sup>, Sonshin Takao<sup>2</sup>, Takashi Aikou<sup>1</sup>

<sup>1</sup>Department of Surgical Oncology and Digestive Surgery and <sup>2</sup>Frontier Science Research Center, Graduate School of Medical and Dental Sciences, Kagoshima University, Kagoshima, Japan

(Accepted 16 December 2005)

### Abstract

**Aims:** Effects of early hyperbaric oxygen therapy (HBOT) on energy metabolism and hepatic regeneration after hepatectomy for liver cancer were prospectively evaluated.

**Materials and methods:** A total of 39 patients who underwent hepatectomy for liver cancer were divided into two groups; 19 patients who received postoperative HBOT (HBOT group) and 20 patients who did not receive HBOT (control group). Each group was further subdivided into noncirrhotic and cirrhotic subgroup. HBOT was performed twice; 3 and 24 hrs after hepatectomy.

**Results:** (1) Hepatic venous oxygen saturation (ShvO<sub>2</sub>) and arterial ketone body ratio (AKBR) in patients with cirrhotic liver were significantly higher in the HBOT group than in the control group, 12 hrs after the operation. (2) The first passage of flatus and peroral intake of meal were obviously earlier in the HBOT group. In addition, the postoperative recovery of serum albumin level was earlier in the HBOT group, particularly in patients with cirrhotic liver. (3) As a result, the hepatic regeneration was promoted in the HBOT group.

**Conclusions:** These results suggest that early postoperative HBOT has a beneficial effect on the hepatic regeneration by improving an imbalance between oxygen demand and delivery, and by enhancing the energy metabolism, and that HBOT is particularly beneficial to patients with cirrhotic liver.

**Key words:** hyperbaric oxygen therapy, postoperative hepatic failure, hepatic regeneration, cirrhotic liver

### Introduction

In the surgical treatment of liver cancer, surgical insult occasionally triggers hepatic failure. In particular, cirrhotic residual liver has insufficient functional reserve. Thus, the hepatic impairment rapidly progresses in patients with cirrhotic residual liver, and they are difficult to treat. It has been reported that decreased oxygen delivery to the liver parenchyma due to microcirculatory failure largely contributes to the progression of hepatic

impairment<sup>1)</sup>. In fact, postoperative mechanical ventilation<sup>2)</sup> and hyperdynamic state<sup>3,4)</sup> have been reported to improve the failure of tissue oxygen metabolism, and to be beneficial in the prevention of hepatic failure. In order to prevent the posthepatectomy hepatic failure through improvement of an imbalance between oxygen demand and oxygen delivery, we have used hyperbaric oxygen therapy (HBOT), and reported increase in dissolved oxygen tension and reduction in the injury of sinusoidal endothelium mediated by inhibition of neutrophil

Address all correspondences and reprint requests to : Dr. Masahiko Sakoda, Department of Surgical Oncology and Digestive Surgery, Graduate School of Medical and Dental Sciences, Kagoshima University, 8-35-1 Sakuragaoka,

Kagoshima 890-8520, Japan  
TEL: +81-099-275-5361, FAX: +81-099-265-7426  
E-mail address: sakoda@m.kufm.kagoshima-u.ac.jp

activation<sup>5)</sup>. It has been reported that HBOT promotes hepatic regeneration in extensively hepatectomized rats<sup>6)</sup>. However, clinical effects of HBOT on energy metabolism, albumin synthesis and liver regeneration in hepatectomized patients are still unknown. The present study was undertaken to evaluate effects of early HBOT on the energy metabolism and on the hepatic regeneration after hepatectomy.

## Materials and methods

### Patients

A total of 39 patients who underwent hepatectomy for liver cancer between September 1998 and May 2000 were subjected to the present study. Twenty seven patients had a primary hepatocellular carcinoma and 12 patients had metastatic tumors in the liver. Nineteen patients (HBOT group) received HBOT and the remaining 20 patients (control group) did not receive HBOT. Based upon the histological activity index (HAI) score, noncancerous region of the liver was classified into 2 categories; cirrhotic (HAI  $\geq$  5) and noncirrhotic (HAI < 5). In the HBOT group, 5 cases were noncirrhotic and the remaining 14 cases were cirrhotic. In the control group, 8 cases were noncirrhotic and the remaining 12 cases were cirrhotic.

Informed consent was obtained from each individual and the protocol was approved by the ethics committee of Kagoshima University Graduate School of Medical and Dental Sciences.

### Hyperbaric oxygen therapy (HBOT)

HBOT was performed twice; 3 hrs and 24 hrs after the hepatectomy, with pure oxygen. Oxygen pressure was then increased at a constant rate to reach a pressure of 2 absolute atmospheres in 15 mins. After 60 min of exposure at 2 absolute atmospheres, patients were decompressed to the normal atmospheric pressure at the same rate as in the compression procedure. Fluid replacement was controlled so that the central venous pressure could be maintained normodynamic.

### Assays

Oxygenation and energy metabolism were evaluated using the following criteria: hepatic venous oxygen saturation (ShvO<sub>2</sub>), arterial ketone body ratio (AKBR) and lactate level. They were measured prior to and

immediately after the operation, prior to and immediately after the first HBOT, 12 hrs after the operation, prior to and immediately after the second HBOT, and 48 hrs after the operation. Clinical items recorded were the date of the first passage of flatus, the date of the first peroral intake of meal, and serum albumin levels on the first, 4th and 7th day after the operation.

### Hepatic regeneration

Calculating the regeneration ratio of residual liver from the data obtained by measurement of resected liver and pre-and-postoperative CT volumetry (Windows98 NCC Volumeter, scanner : Epson GT-8000), hepatic regeneration was estimated in 22 patients (11 cases of the HBOT group and 11 cases of the control group). The following formula was used in calculating the regeneration ratio of residual liver;

regeneration ratio of residual liver (%) = [ total hepatic volume 2weeks after operation - (preoperative total hepatic volume - total resected liver volume)] / resected noncancerous liver volume X 100

### Statistical Analysis

We expressed values as means  $\pm$  SD and for statistical analysis, Mann-Whitney test was used. P < 0.05 was considered to be statistically significant.

## Results

The clinical features of 39 patients who underwent hepatectomy are shown in Table 1. There were no significant differences between the HBOT and the control group, with regard to age, sex, indocyanine green retention rate at 15 min. after injection (ICGR15), extent of hepatic resection, and blood loss during the operation.

### 1. Oxygenation and energy metabolism

#### 1) ShvO<sub>2</sub>

Although statistically insignificant, ShvO<sub>2</sub> in patients with noncirrhotic residual liver was higher in the HBOT group than in the control group, 12 hrs after the operation. In patients with cirrhotic residual liver, ShvO<sub>2</sub> was 74.5  $\pm$  5.7 % in the HBOT group, whereas it was 66.8  $\pm$  9.2 % in the control group, 12 hrs after the operation. ShvO<sub>2</sub> was significantly elevated in the HBOT group (Fig.1).

Table 1. Background factors in HBOT and Control groups.

Group	Control group (n=20)	HBOT group (n=19)	p Value
Age (years)	64±10	65±7	0.67
Sex, male/female	17/3	15/4	0.62
ICGR15 (%)	12.6±5.5	13.9±8.0	0.61
Blood loss (g)	1476±1257	1498±1430	0.96
Extent of hepatic resection (cases)			
enucleation or subsegmentectomy	6	7	
segmentectomy	9	7	
lobectomy	5	5	0.86

ICGR15: indocyanine green retention test at 15 min after injection.

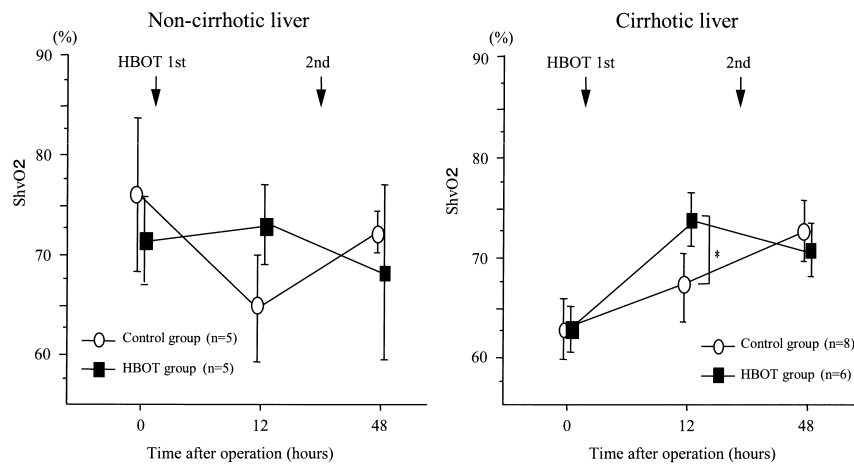


Fig. 1. Changes of hepatic venous oxygen saturation (ShvO<sub>2</sub>). Bars show mean ± SD. \*P<0.05

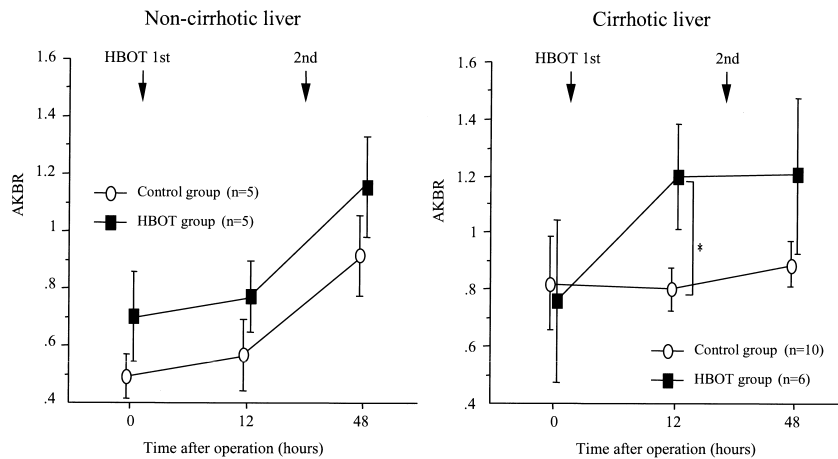


Fig. 2. Changes of AKBR values in plasma after operation. Bars show mean ± SD. \*P<0.05

## 2) AKBR

In both the HBOT and the control group, AKBR in the noncirrhotic residual liver gradually increased following the operation for 48 hrs. There was no significant difference between these two groups. In the

cirrhotic residual liver, AKBR was maintained at a low level in the control group, but AKBR was markedly increased in the HBOT group. Twelve hrs after the operation, AKBR was 1.2±0.4 in the HBOT group, while it was 0.8±0.2 in the control group. The difference was

statistically significant (Fig.2).

3) Lactate

In patients with noncirrhotic residual liver, the decline of lactate level was significantly more rapid in the HBOT group than in the control group. There was no significant difference in the cirrhotic residual liver (Fig.3).

2. First flatus and first meal after the operation

The first passage of flatus occurred  $2.6 \pm 1$  days after the operation in the HBOT group. It occurred  $3.3 \pm 0.9$  days after in the control group. The difference between two groups was statistically significant. The first meal was taken  $3.8 \pm 1.4$  days after the operation in the HBOT group, while it was taken  $4.7 \pm 1.6$  days after in the control group. The HBOT group took the first meal after

the operation earlier than the control group (Table 2).

3. Postoperative serum albumin level

In patients with noncirrhotic residual liver, the serum albumin level was maintained at a relatively high level on the 4th and on the 7th postoperative day, and there was no significant difference between the HBOT and the control group. In patients with cirrhotic residual liver, the serum albumin level in the control group was  $3.86 \pm 0.28$ ,  $3.67 \pm 0.37$  and  $3.65 \pm 0.43$  g/dl on the first, on the 4th and on the 7th postoperative day, respectively. The serum albumin level gradually declined. In the HBOT group, it was  $3.75 \pm 0.22$ ,  $3.73 \pm 0.37$  and  $3.76 \pm 0.44$  g/dl on the first, 4th and 7th postoperative day, respectively. The recovery of serum albumin level was favorable in this group (Fig.4).

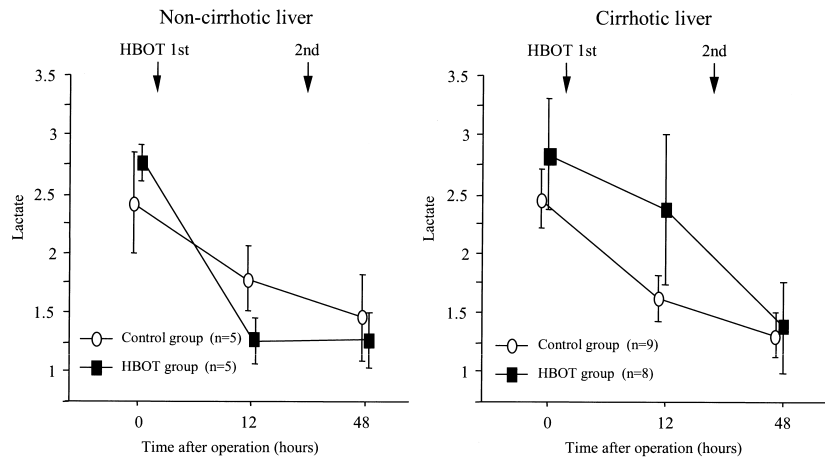


Fig. 3. Changes of Lactate values in plasma after operation. Bars show mean  $\pm$  SD.

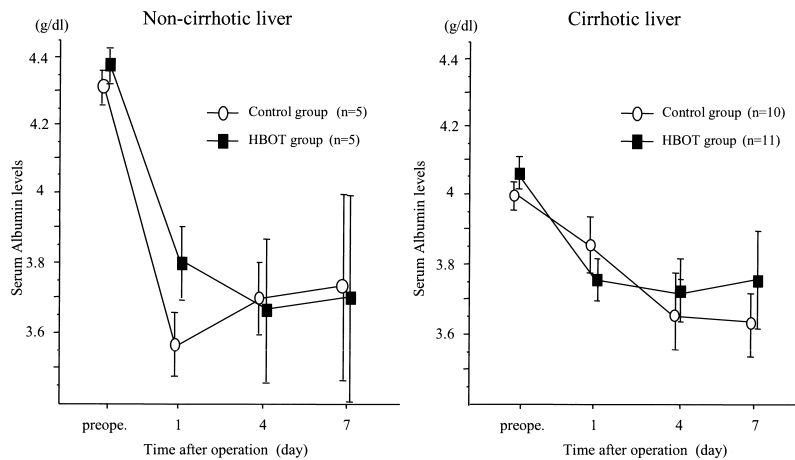


Fig. 4. Changes of serum Albumin levels after operation. Bars show mean  $\pm$  SD.

Table 2. Postoperative recovery of bowel function. The period of first flatus and start of oral diet after operation.

	First flatus after operation (day)	Start of oral diet after operation (day)
Control group (n=17)	3.3±0.9	4.7±1.6
HBOT group (n=19)	2.6±1.0*	3.8±1.4

Results are expressed as mean±SD. \*P<0.05 compared with Control group, Mann-Whitney test.

Table 3. Comparison of regeneration ratio of residual liver 2 weeks after operation.

	Non-cirrhotic liver		Cirrhotic liver	
	Control (n=4)	HBOT (n=3)	Control (n=7)	HBOT (n=8)
Regeneration ratio (%)	59±28	78±22	52±16	62±9

Results are expressed as mean±SD. There were no significant differences between the Control groups and the HBOT groups.

#### 4. Hepatic regeneration

The regeneration ratio of noncirrhotic residual liver was 78±22 % in the HBOT group, while it was 59±28 % in the control group. The regeneration ratio of cirrhotic residual liver was 62±9 % in the HBOT group, whereas it was 52±16 % in the control group. Although statistically insignificant, the mean regeneration ratio was slightly higher in the HBOT group than in the control group (Table 3).

### Discussion

The rationale for using hyperbaric oxygen is the improvement of tissue hypoxia through the inhalation of high concentration oxygen under a hyperbaric condition, resulting in increased blood oxygen tension (10-20 times) and also in increased distance of interstitial oxygen diffusion (2-3 times)<sup>7</sup>. HBOT is a therapy with some well established indications; Decompression sickness, air embolism, carbon monoxide poisoning, gas gangrene, sudden deafness, chronic refractory osteomyelitis, osteoradionecrosis, ileus, cerebrovascular injuries and acute myelopathies are the indications for HBOT<sup>8</sup>. Recently, HBOT has also been indicated to serious infections<sup>9</sup>, hyperbilirubinemia<sup>10, 11, 12</sup>, Crohn's disease<sup>13</sup> and ulcerative colitis<sup>14</sup>. Experimentally, high oxygen tension has been shown to reduce bacterial translocation<sup>15</sup>. HBOT has also been shown to reduce vascular endothelial damage through suppression of neutrophil adhesion mediated by inhibition of leukocyte migration and also by blockade of adhesion molecules<sup>16</sup>. Hence, beneficial effects of HBOT have been attributed to two mechanisms: 1) the prevention of failure in tissue oxygen metabolism through increase in dissolved oxygen and 2) the reduction of organ injuries through

the inhibition of neutrophil activation and subsequent cytokine release. In an attempt to prevent hepatic failure after hepatectomy, the present authors have been performing early postoperative HBOT which potentially improves an imbalance between oxygen demand and oxygen delivery. In the present study, we have examined effects of HBOT on the energy metabolism and on the hepatic regeneration, and found that the early use of HBOT after hepatectomy improves an imbalance between oxygen demand and oxygen delivery, and also enhances the energy metabolism particularly in patients with cirrhotic residual liver. The results suggest that HBOT promotes albumin synthesis and possibly hepatic regeneration as well.

Comparing changes in ShvO<sub>2</sub> and AKBR, the tissue oxygen metabolism appears to be more benefited in patients with cirrhotic residual liver by HBOT performed 3 hrs after the operation. There has been a similar previous report that HBOT after TAE for hepatocellular carcinoma improved hepatic energy production<sup>17</sup>. In the present study, HBOT has been shown to be of benefit in patients with cirrhotic residual liver. The noncirrhotic liver may have sufficient recuperative power even in the absence of oxygen delivery support. In contrast, the cirrhotic liver is less tolerant of insult because its functional reserve is reduced. Hence, HBOT may be more beneficial in the cirrhotic liver than in the noncirrhotic liver. Since there are many patients with reduced hepatic functional reserve, the beneficial effect of HBOT on patients with cirrhotic residual liver has a clinical significance.

The first passage of flatus after the operation was earlier in the HBOT group than in the control group. It is well known that HBOT prevents postoperative ileus. HBOT may facilitate the passage of flatus by improving

the splanchnic circulation. The facilitation of flatus passage may have contributed to the earlier first meal intake after the operation in the HBOT group. The serum albumin level in patients with cirrhotic residual liver progressively declined during the first 7 days after the operation in the control group, but the HBOT group showed an earlier recovery. Experimentally, it has been shown that increased tension of dissolved oxygen facilitates albumin secretion from cultured liver cells<sup>18)</sup>. Improvement of an imbalance between oxygen demand and oxygen delivery enhances the energy metabolism. The earlier peroral nutrition improves the splanchnic circulation, and thus increases the oxygen and substrate delivery to the liver. Probably these effects altogether contributed to the earlier recovery of the serum albumin level. As a result, although there was no significant difference, postoperative duration of hospitalization was shortened a little in the HBOT group (data not shown).

In extensively hepatectomized rats, HBOT has been reported to promote hepatic regeneration<sup>9)</sup>. In the present clinical evaluation of HBOT, we estimated the hepatic regeneration based on the regeneration ratio of residual liver 2 weeks after the operation. The regeneration ratio was calculated from the data obtained by CT volumetry and postoperative measurement of resected liver, and found that in both cirrhotic and noncirrhotic patients, the ratio was slightly higher in the HBOT group than in the control group. Hepatic blood flow, oxygen delivery and growth factors may contribute to hepatic regeneration. The present data suggest that HBOT may promote hepatic regeneration through its beneficial effects not only on the relationship between oxygen demand and oxygen delivery, but also on the intestinal absorption, as in the case of albumin synthesis.

To summarize, the early use of HBOT after hepatectomy improves an imbalance between oxygen demand and oxygen delivery, and enhances the energy metabolism particularly in the cirrhotic residual liver. In addition, HBOT has an added benefit of allowing peroral nutrition to be taken earlier. As a result, HBOT promotes albumin synthesis and possibly hepatic regeneration as well. HBOT is a specific therapeutic measure to ensure adequate oxygen delivery independent of transfusion and also of fluid replacement. This approach is particularly of benefit in patients with cirrhotic residual liver who are prone to retain body water.

## Acknowledgements

This work was supported in part by Grants-in-Aid for Scientific Research from the Japan Society for the Promotion of Science (No. 14370359).

## References

- 1) Kamada T, Sato N, Koyama M. Hemoperfusion and oxygen sufficiency in chronically diseased liver in situ measured by organ reflectance spectrophotometry. *Gastroenterology* 1980; 79: 1132.
- 2) Matsumata T, Kanematsu T, Okudaira Y, Sugimachi K, Zaitu A, Hirabayashi M. Postoperative mechanical ventilation preventing the occurrence of pleural effusion after hepatectomy. *Surgery* 1987; 102: 493-497.
- 3) Nonami T, Asahi K, Harada A, Nakao A, Takagi H. Effect of hyperdynamic circulatory support on hepatic hemodynamics, oxygen supply and demand after massive hepatectomy. *Surgery* 1991; 109: 277-283.
- 4) Ueno S, Tanabe G, Yamada H, Kusano C, Yoshidome S, Nuruki K, et al. Response of patients with cirrhosis who have undergone partial hepatectomy to treatment aimed at achieving supranormal oxygen delivery and consumption. *Surgery* 1998; 123: 278-286.
- 5) Ueno S, Tanabe G, Kihara K, Aoki D, Arikawa K, Dogomori H, et al. Early post-operative hyperbaric oxygen therapy modifies neutrophil activation. *Hepato-Gastroenterology* 1999; 49: 1798-1799.
- 6) Matsuda N, Onda M, Moriyama Y, Kim DY, Yoshimura S, Matsuda T, et al. The effect of hyperbaric oxygen therapy on hepatic regeneration after hepatectomy. *Jpn J Hyperbar Med* 1990; 25: 129-135.
- 7) Boerema I, Meyne NG, Brummelkamp WK, Bouma S, Mensch MH, Kamermans F. Life without blood. A study of the influence of high atmospheric pressure and hyperthermia on dilution of the blood. *J cardiovasc Surg* 1960; 1: 133-146.
- 8) Yamamoto I, Komori K, Seki T, Nemoto M, Inokuchi S, Sawada Y. Indications, Clinical results and incidental problems of hyperbaric oxygenation. *ICU & CCU* 1997; 21: 849-859.
- 9) Damir K, Nikica D, Ivo T, Josko J, Nadan P.

Hyperbaric oxygenation as adjuvant therapy to surgery of emphysematous cholecystitis. *Hepato-Gastroenterology* 1999; 46: 775-777.

- 10) Arikawa K, Kubo H, Dohgomori H, Morikawa G, Kawakami M, Yoshimura N, et al. Effectiveness of hyperbaric oxygen therapy for hyperbilirubinemia. *Jpn J Hyperbar Med* 1997; 31: 239-244.
- 11) Dohgomori H, Arikawa K, Kubo H, Yoshimura N. Hyperbaric oxygenation therapy to treat hyperbilirubinemia. *ICU & CCU* 1999; 23: 139-144.
- 12) Hosaka S, Tsuji T, Inoue K, Kanemitsu K. The usefulness of hyperbaric oxygen therapy for prolonged jaundice after hepatectomy. *Jpn J Gastroenterol Surg* 1999; 32: 896-900.
- 13) Charles M. Hyperbaric oxygen therapy for perineal Crohn's disease. *Am J Gastroenterol* 1999; 94: 318-321.
- 14) Kuroki K, Masuda A, Uehara H. A new treatment for toxic megacolon. *Lancet* 1998; 352: 782.
- 15) Roberto G, Wesley A. Effects of hyperoxia on bacterial translocation and mortality during gut-derived sepsis. *Arch Surg* 1996; 131: 57-62.
- 16) Zamboni WA, Roth AC, Russell RC. Morphological analysis of the microcirculation during reperfusion of ischemic skeletal muscle and the effect of hyperbaric oxygen. *Plast Reconstr Surg* 1993; 91: 1110-1123.
- 17) Kato H, Yoshikawa M, Ebara M, Furuyama N, Ohto M. Hyperbaric oxygen therapy for hepatic dysfunction caused by transcatheter arterial embolization for hepatocellular carcinoma. *Kanzou* 1993; 34: 975-982.
- 18) Yanagi K, Miyoshi H, Ohshima N. Improvement of metabolic performance of hepatocytes cultured in vitro in a packed-bed reactor for use as a bioartificial liver. *ASAIO J* 1998; 44: 436-440.

## 肝切除後エネルギー代謝及び肝再生に対する術後早期高気圧酸素療法の効果の検討

迫田 雅彦<sup>1</sup>, 上野 真一<sup>1</sup>, 久保 文武<sup>1</sup>, 樋渡 清司<sup>1</sup>, 木原 研二<sup>1</sup>,  
新地 洋之<sup>1</sup>, 前村 公成<sup>1</sup>, 野間 秀歳<sup>1</sup>, 高尾 尊身<sup>2</sup>, 愛甲 孝<sup>1</sup>

<sup>1</sup>鹿児島大学医学部腫瘍制御学・消化器外科学, <sup>2</sup>鹿児島大学フロンティアサイエンス研究推進センター

**【目的】** 肝癌の外科的治療においては、その侵襲が引き金となり肝不全へ陥ることがある。特に肝硬変を有する症例は肝予備能が十分でないため肝障害が急激に増悪し治療に難渋する。われわれは、肝切除後肝不全予防策の一つとして酸素需給動態改善目的に術後早期の高気圧酸素療法を行い、その溶存酸素増強効果や、あるいは好中球活性化抑制作用による類洞内皮障害軽減効果を有することを報告してきたが、肝切除後のエネルギー代謝、アルブミン合成能、肝再生に対し高気圧酸素療法がどのような影響を及ぼすかは不明である。そこで今回、肝切除手術後のエネルギー代謝ならびに肝再生に及ぼす術後早期の高気圧酸素療法の影響を検討した。

**【対象・方法】** 当科における1998年9月から2000年5月までの肝癌切除39症例（原発性肝癌27例、転移性肝癌12例）を対象に術後早期高気圧酸素療法施行群19例（H群）と非施行群20例（C群）の2群に分類し、さらに両群をその非癌部HAI scoreをもとに非硬変肝と硬変肝に細分類した。高気圧酸素療法は100%酸素呼吸下、絶対2気圧、60分間の条件で肝切除後3時間および24時間の計2回施行し、輸液管理は中心静脈圧を指標としてnormodynamicに行った。検討項目として酸素化・エネルギー代謝の指標には肝静脈血酸素飽和度、動脈血中ケトン体比、血中乳酸値を術前、術後、高気圧酸素療法1回目前後、術後12時間、高気圧酸素療法2回目前後、術後48時間に測定した。臨床的項目として術後排ガス出現日、食事開始日、術後1, 4, 7日目の血中アルブミン値の推移を検討した。肝再生については22例（H群11例、C群11例）について術後2週間の残肝復元率をCT volumetryにて算出した。

**【結果】** ①術後12時間の肝静脈血酸素飽和度及び動脈血中ケトン体比は硬変肝においてH群が有意に高値を示した。②H群では排ガス、食事開始が明らかに早期で、術後アルブミン値の回復もとくに硬変肝で良好であった。③この結果、残肝復元率もH群でより促進される傾向が認められた。

**【結論】** 肝切除後早期の高気圧酸素療法は特に硬変肝において、肝酸素需給動態を改善しエネルギー代謝を高める。さらに早期経口摂取を可能にすることと併せて、アルブミン合成能や肝再生に貢献することが指摘された。高気圧酸素療法は輸血や輸液量に依存しない酸素供給増強法であることから、水分貯留傾向のある肝硬変の病態により即した方法であると思われる。