

## Normal Delivery Following R0 Gastrectomy for Stage IV Gastric Cancer

Sumiya Ishigami, Shinichi Ueno, Yoshiaki Kita, Takaaki Arigami, Yasuto Uchikado, Hideo Arima, Hiroshi Kurahara, Hiroshi Okumura, Masataka Matsumoto, Yuko Kijima, Masaki Kitazono, and Shoji Natsugoe,

Digestive Surgery, Surgical Oncology, Kagoshima University School of Medicine, Kagoshima, JAPAN.

### Abstract

The authors present a case in which a patient with stage IV gastric cancer underwent R0 gastrectomy and delivered a healthy neonate three years postoperatively. The patient was 36-year-old female, who was admitted to Kagoshima University Hospital after developing epigastric pain. Endoscopy revealed type 4 gastric cancer in the middle third of the stomach. Total gastrectomy with lymphadenectomy was performed. The tumor, which was extirpated macroscopically, was found to have invaded the pancreas and localized dissemination was noted in the mesocolon. Postoperatively the patient underwent S-1 administration with withdrawal term, she noticed no recurrence noted during follow-up. After pregnancy was confirmed in April 2003, S-1 and radiological examinations were discontinued and a healthy neonate was delivered after 8 months. The patient and her child are in good health, with no evidence of recurrent tumor in 2010. As normal delivery is a rare event after diagnosis of stage IV gastric cancer, the authors present this case and discuss the relevant literature.

**Key words:** Stage IV gastric cancer, pregnancy, S-1 Adverse effect.

### Introduction

Gastric cancer is reported to have poor postoperative outcome<sup>1)</sup>. Furthermore, it is suggested that hormonal alterations during pregnancy promote gastric cancer cell proliferation<sup>2)</sup>, and in advanced gastric cancer, might influence disease progression not only preoperatively but also postoperatively. On the other hand, pregnancy after gastric cancer surgery involves many risks to the fetus related to anticancer medication and X-ray exposure as a result of postoperative follow-up investigations. We encountered a patient with stage IV gastric cancer who underwent R0 gastrectomy and continuous S-1 postoperative adjuvant chemotherapy. During the course of chemotherapy, pregnancy was confirmed and the patient delivered a healthy neonate 3 years into the postoperative course.

### Case Report

A 36-year-old woman was admitted to Kagoshima University Hospital with a complaint of epigastric pain. Endoscopy revealed type 4 gastric cancer in the middle third of the stomach and histological analysis of biopsy specimens showed poorly differentiated adenocarcinoma. On Oct 2000, the patient underwent total gastrectomy with D2 lymph node dissection and additional resection of the pancreatic tail and spleen due to direct tumor invasion. As disseminated tumor was identified in the transverse mesocolon, partial colectomy was necessary and the tumor was macroscopically extirpated (R0 gastrectomy) (Figure 1).

Macroscopic examination of the resected gastric primary tumor revealed a 10x11 cm lesion infiltrating the normal gastric tissue. Histopathologic staging was as follows: T3 (invasion to the serosa), N2 (lymph node metastasis was found in nodes around the splenic

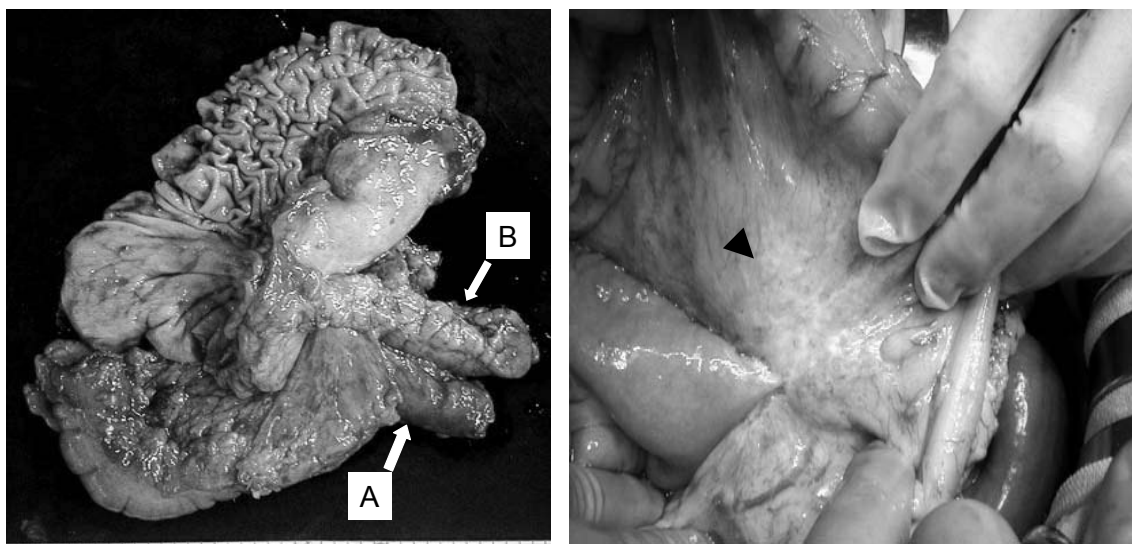


Fig.1. Gastric cancer invaded into transverse colon (A) and pancreas (B). Disseminated tumor was identified in the mesocolon (arrow head).

artery), H0 (no hepatic metastasis), P1 (carcinomatous invasion of the peritoneum), indicating stage IV disease. Although the patient underwent R0 gastrectomy, adjuvant chemotherapy was considered appropriate in view of the high risk of recurrence. After receiving the informed consent of postoperative adjuvant chemotherapy of S-1, S-1 was administered at 100 mg daily, before being tapered to 50 mg daily for the next 2 and a half years. No sign of recurrent gastric cancer has been noted during follow-up.

In April 2003, the patient realized that she was pregnant. S-1 was contraindicated for pregnant patients because of its teratogenesis. We recommended the patient discontinued with pregnancy. However, she was very keen to continue with the pregnancy, chemotherapy of S-1 and radiological investigations were both stopped and the pregnancy was maintained. Abdominal ultrasonography and measurement of tumor markers were periodically performed as postoperative follow-up. On December 2003, she had an uncomplicated delivery of a healthy infant. The patient and her child remain in good health with no sign of tumor recurrence in 2010.

## Discussion

Although a significant relationship between gastric cancer progression and pregnancy has been reported, there are few reports describing a pregnancy during and after the post-gastrectomy course. In the current case, the tumor was assessed as stage IV gastric cancer due to localized peritoneal dissemination, a stage that is generally associated with poor prognosis, even after R0 gastrectomy<sup>3)</sup>. To prevent tumor recurrence, S-1 was administered as a postoperative adjuvant agent. During the period of close postoperative follow-up by our outpatient department, the patient realized that she had conceived and was in the 8th week of gestation. She had thus been exposed to S1 during the period of organogenesis. However, a gynecologist recommended that continuation of the pregnancy was appropriate obstetrician because she had only been receiving 50 mg of S-1 / day and approximately 8mGy of X radiation - doses that are far below the threshold level (fetal deformation is associated with >3mg/kg/day of S-1 and >100mGy of X radiation)<sup>4,5)</sup>.

Jasper has suggested that estrogen exhibits a trophic effect on gastric cancer cell lines which is also observed in murine models of gastric cancer, and that type 4 gastric tumors often express estrogen receptors, which may be associated with poor prognosis<sup>2)</sup>. Maintaining pregnancy

seems to elevate the risk of relapse of gastric cancer due to extreme hormonal changes. Fortunately, despite having discontinued adjuvant chemotherapy during the pregnancy, no sign of disease recurrence has occurred in the present case. Nonetheless, continuing pregnancy during the postoperative course is not recommended in stage IV gastric cancer.

## References

- 1) Kath R, Fiehler J, Scheider CP, Hoeffken K. Gastric cancer in very young adults: apropos four patients and a review of the literature. *J Cancer Res Clin Oncol* 2000; 126: 233-237.
- 2) Jaspers VK, Gillessen A, Quakernack K. Gastric cancer in pregnancy: Do pregnancy, age or female sex alter the prognosis? Case reports and review. *Eur J Obstet Gynecol Reprod Biol.* 1999; 87: 13-22.
- 3) Kobayashi A, Nakagohri T, Konishi M, Inoue K, Takahashi S, Itou M, et al. Aggressive surgical treatment for T4 gastric cancer. *J Gastrointest Surg.* 2004; 8: 464-70.
- 4) Shinomiya M, Imamura K, Izumi K. Reproductive and developmental toxicity study of a new antineoplastic agent, S-1. *J Toxicol Sci.* 1996; 21: 589-602.
- 5) Kusama T, Ota K. Radiological protection for diagnostic examination of pregnant women. *Congenit Anom.* 2002; 42:10-4.

## 根治切除後に正常妊娠を経験したIV期胃癌の1例

石神 純也, 上野 真一, 喜多 芳昭, 有上 貴明, 内門 泰斗, 有馬 豪男, 蔵原 弘,  
奥村 浩, 松本 正隆, 喜島 祐子, 北蘭 正樹, 夏越 祥次

鹿児島大学腫瘍制御学消化器外科

**はじめに：**われわれは根治切除後に正常妊娠と出産を経験，以降無再発生存中の4期胃癌の1例を経験したので報告する。

**症例：**症例は36歳の女性。心窩部痛を主訴に鹿児島大学病院を受診した。胃内視鏡検査で胃体部を中心とする4型の胃癌を指摘された。腫瘍は臍体と結腸間膜に浸潤しており限局性の播種も認められた。胃全摘，横行結腸切除，臍体尾部切除，脾摘を施行し，根治切除された。術後S1の予防投与が行われ，再発の兆候は見られなかった。化学療法継続中の術後2年目に妊娠を自覚した。S1による胎児への影響を考慮して出産の中止を説明したが，拳児の希望が強く，化学療法を中止したのち，妊娠を継続した。8ヶ月後に健児を出産，術後9年を経過して再発の兆候は認められない。

**まとめ：**高度進行胃癌治療中の正常分娩の1例を経験した。抗がん剤投与中の妊娠に対しては中止するように勧めるべきであるが，拳児の希望が強い場合は，投薬の中止，使用中であった薬剤の催奇形性などを加味して分娩・児のリスクを評価する必要がある。